



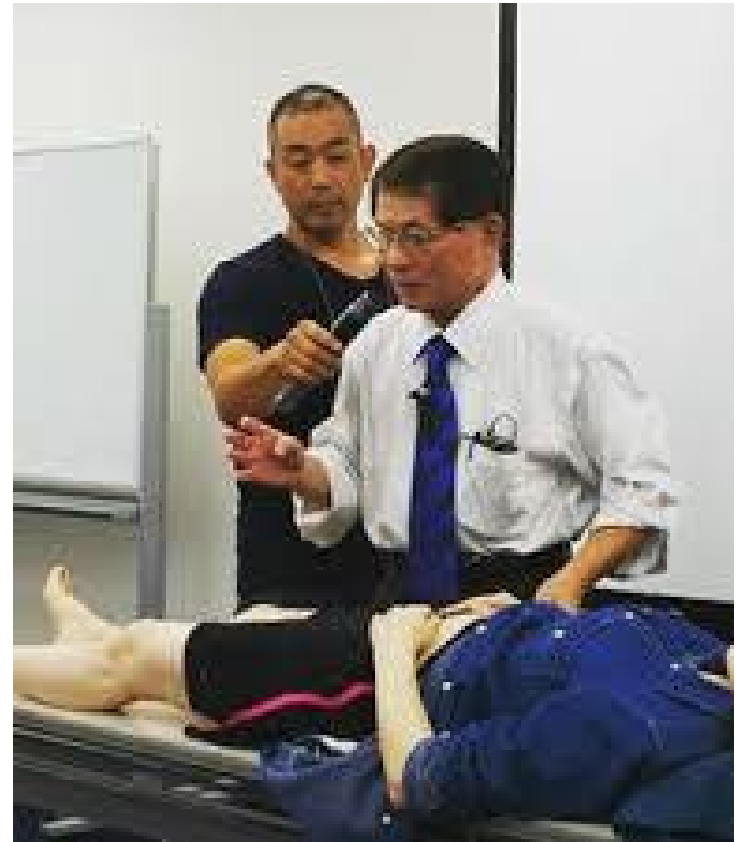Miyawaki EV
Treatment
宮脇奇経治療

Masanari Nakano

よくわかる奇経治療

第2版

宮脇 和登 著



Easy EV treatment x Yuki Miyawaki



What is Miyawaki EV Treatment?

宮脇奇経治療とは

- ① EV 8 Pulses 奇経八脉
- ② Miyawaki Super 4 宮脇スーパー4
- ③ 3変法

EV Therapy treats using above 15 patterns according to the patient's symptoms

の15パターンを患者の症状に合わせて用いる治療法。

EV 8	Du Mai	SI3	Yang Qiao	BL62
	Yang Wei	TW5	Dai Mai	GB41
	Ren Mai	LU7	Yin Qiao	KD6
	Yin Wei	PC6	Chong Mai	SP4
Miyawaki Super 4	H. Yang Ming	ST43	F. Yang Ming	LI4
	H. Shao Yin	HT5	F. Jue Yin	LV3
Variant 3	LV3 — PC6		PC6 — LV3	
	HT5 — SP4			

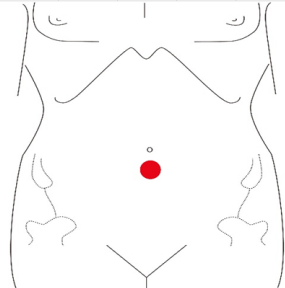
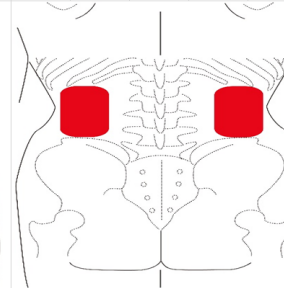
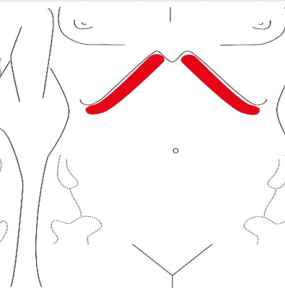
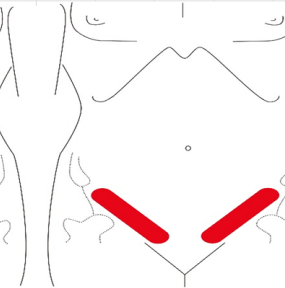
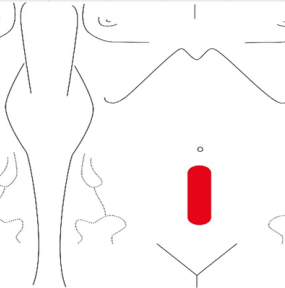
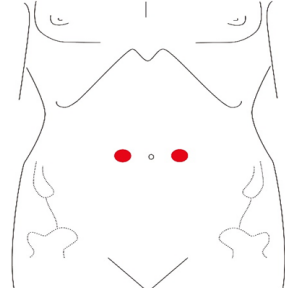
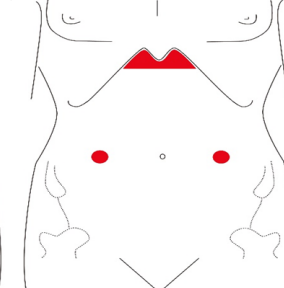
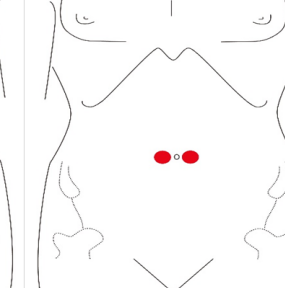
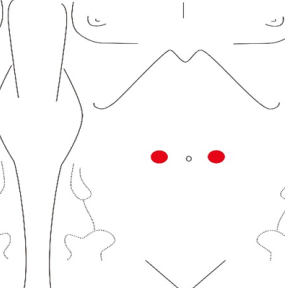
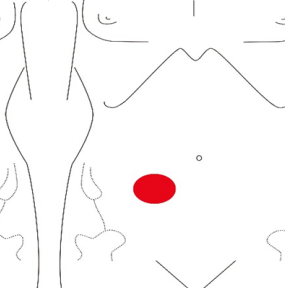
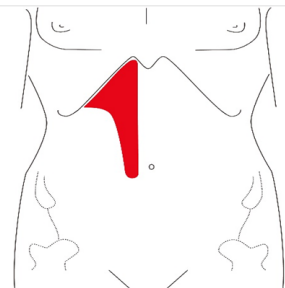
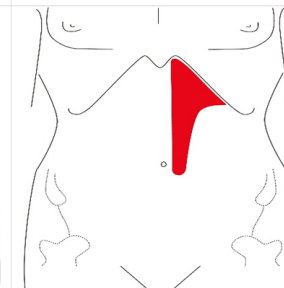
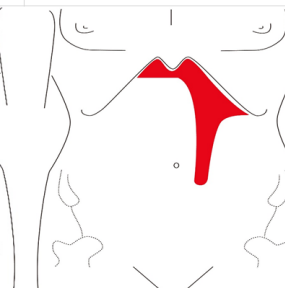
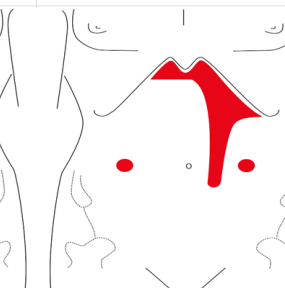
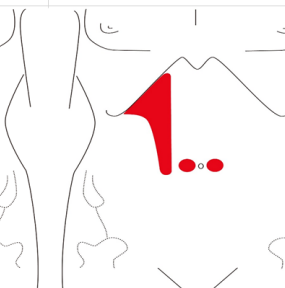
Point Location for 8 Confluent Points and Miyawaki Super 4

S I 3		B L 6 2		T W 5		G B 4 1	
	腕骨穴から中手指節関節の間の圧痛硬結		外踝の下、腿の前の圧痛硬結		陽池穴の上2寸、腿と骨の間の圧痛硬結		第4第5中足骨の間の圧痛硬結
L U 7		K D 6		P C 6		S P 4	
	橈骨茎状突起を越えた陥凹部の圧痛硬結		内踝の下、腿の後ろの陥凹部の圧痛硬結		大陵穴の上2寸の圧痛硬、①腿の間 ②腿の尺側		太白穴を押し上げて止まる所の圧痛硬結
L I 4		S T 4 3		L V 3		H T 5	
	①第1第2中手骨の間、②三間の上の圧痛硬結		第2第3中足指節関節の後の圧痛硬結		第1第2中足骨接合部の圧痛硬結		腿の尺側、神門の上の圧痛硬結

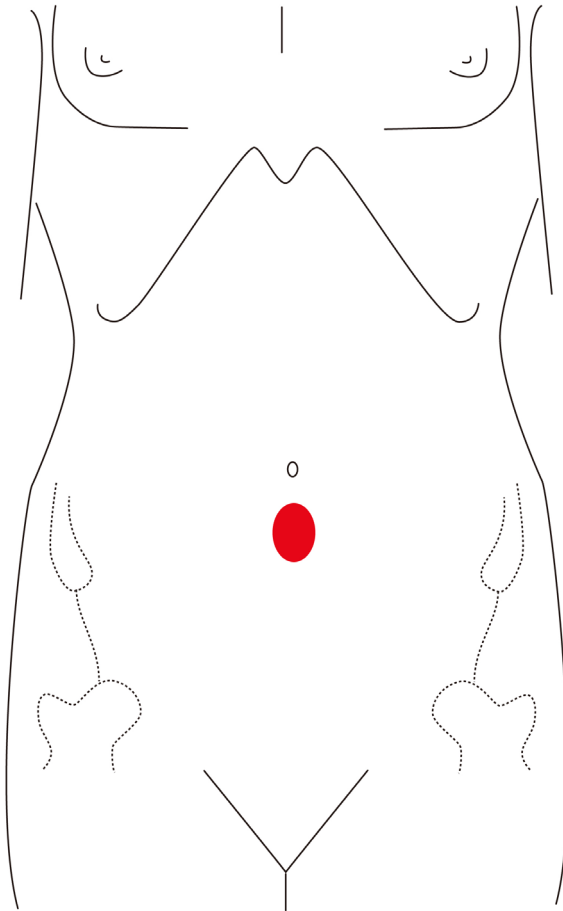
Miyawaki EV Abdominal Diagnosis®

- **The 15 patterns are diagnosed by Miyawaki EV Abdominal Diagnosis®**

宮脇奇經腹診®

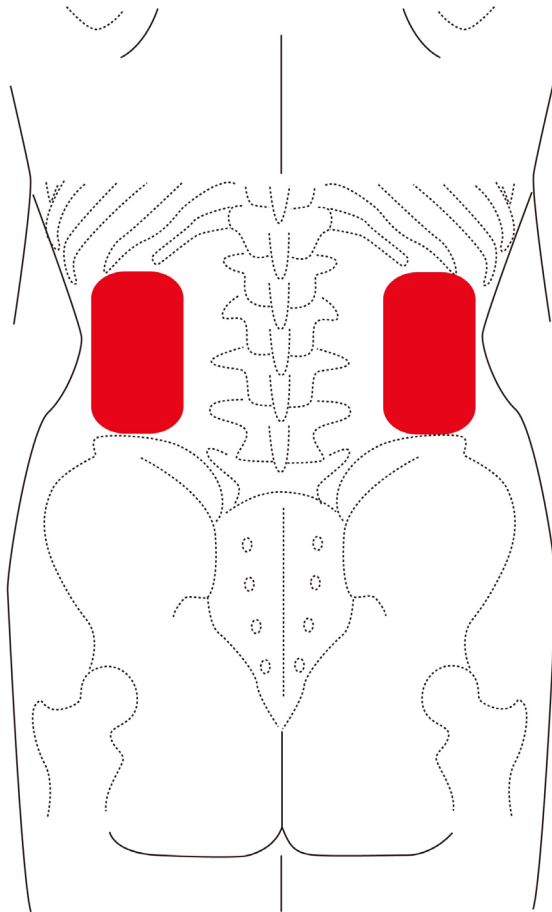
				
督脉 後谿—申脈	陽蹻脉 申脈—後谿	陽維脉 外關—臨泣	帶脉 臨泣—外關	任脉 列缺—照海
				
陰蹻脉 照海—列缺	陰維脉 內關—公孫	衝脉 公孫—內關	手陽明脉 合谷—陷谷	足陽明脉 陷谷—合谷
				
手少陰脉 通里—太衝	足厥陰脉 太衝—通里	太衝—內關	內關—太衝	通里—公孫

Du Mai



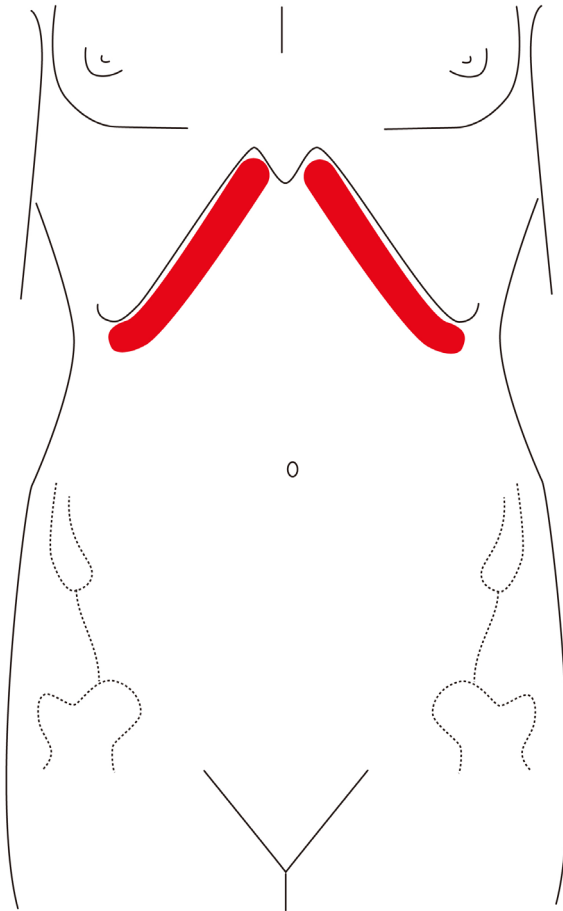
Tightness and pressure
pain along the centerline
of the lower abdomen,
around CV6, CV7

Yang Qiao Mai



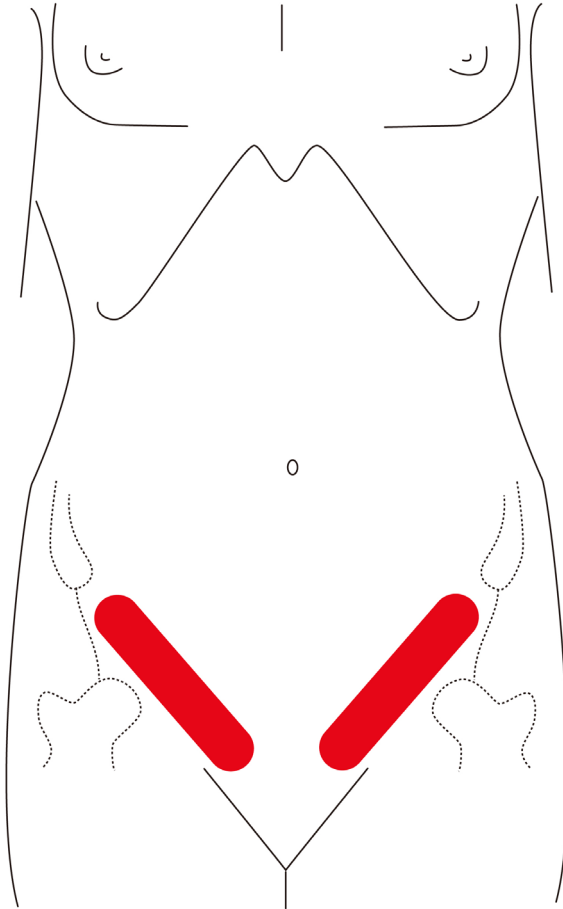
In the area where a horizontal line is drawn across from T12, above the iliac crest and hugged by a line drawn vertically from BL23

Yang Wei Mai



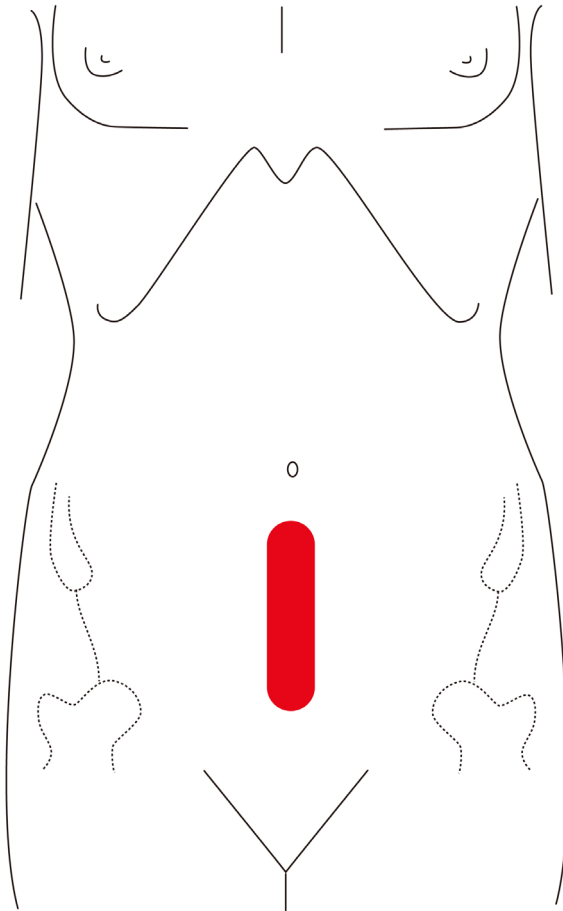
Reaction appears along the underside of the front rib cage. Diagnose while comparing with Dai Mai.

Dai Mai



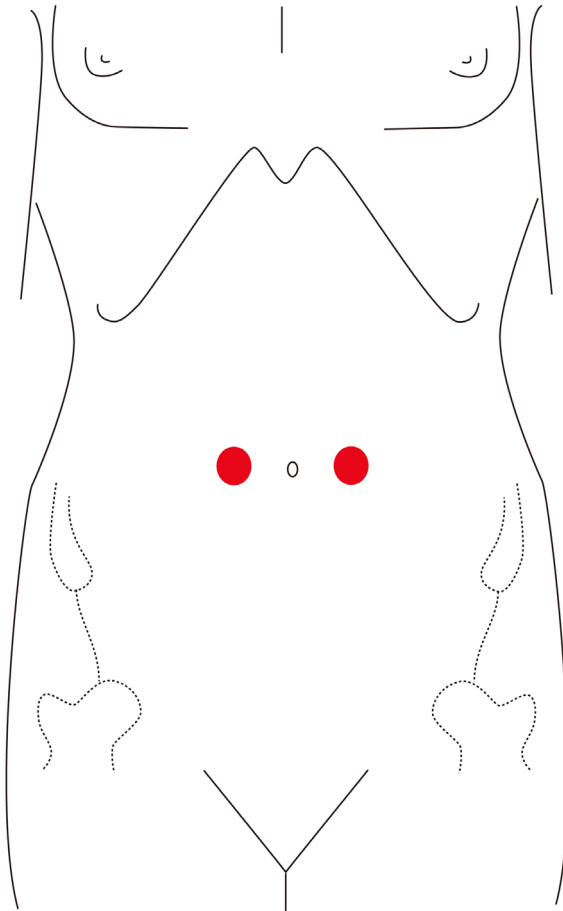
Slightly above the
inguinal ligament on both
sides of the lower
abdomen

Ren Mai



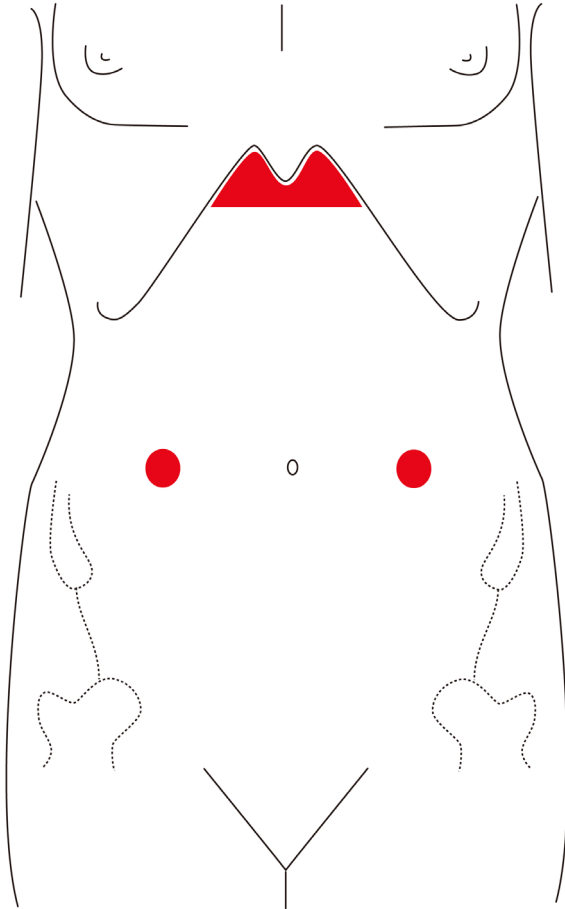
The centerline along the lower abdomen, easy to find by examining the vicinity of CV4, CV5

Yin Qiao Mai



ST25 on both sides

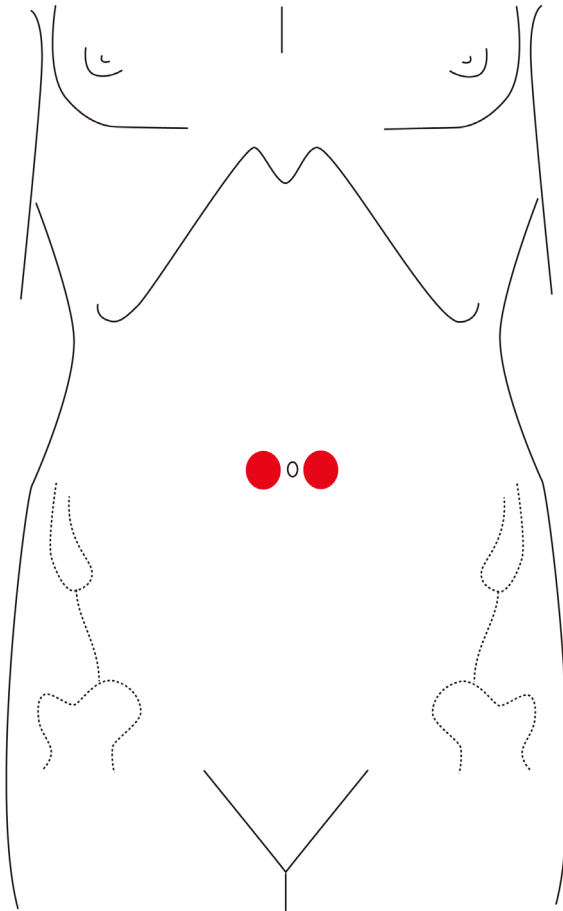
Yin Wei Mai



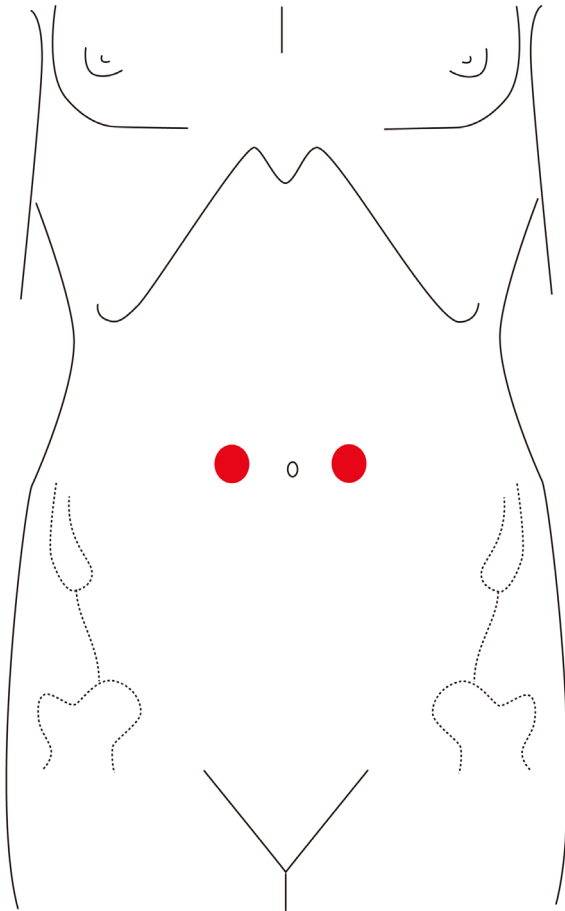
Appears in both SP15
and in the epigastric
fossa

Chong Mai

KD16 on both sides

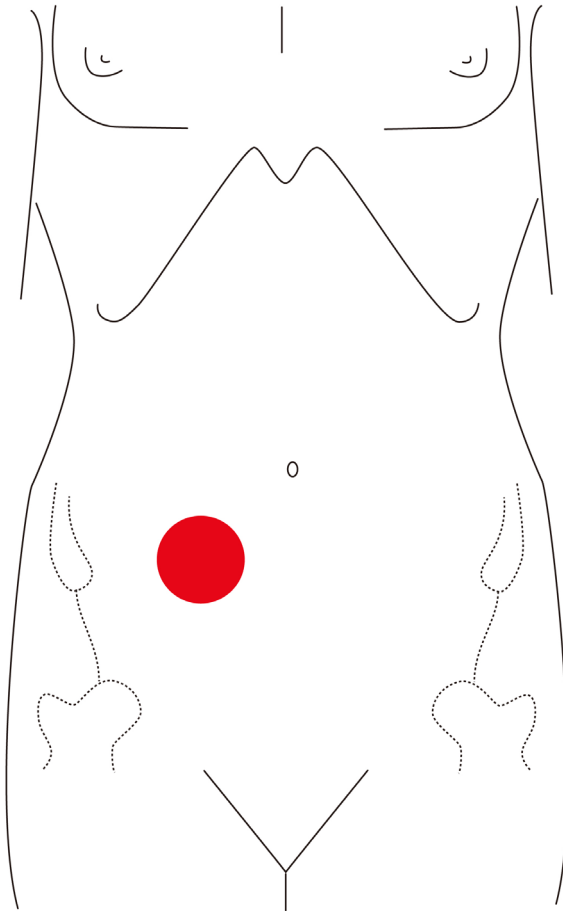


Hand Yang Ming Mai



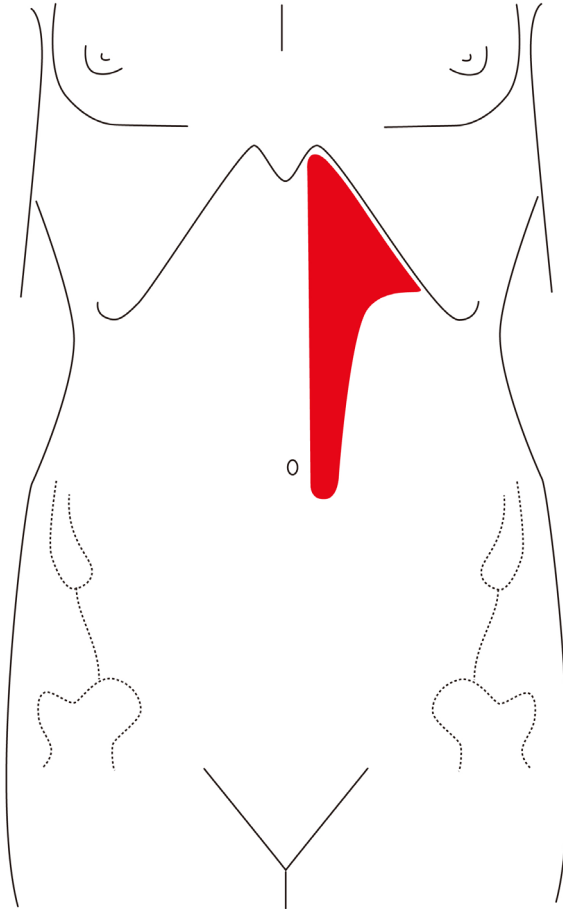
In both ST25 but reaction is shallower compared to Yin Qiao Mai

Foot Yang Ming Mai



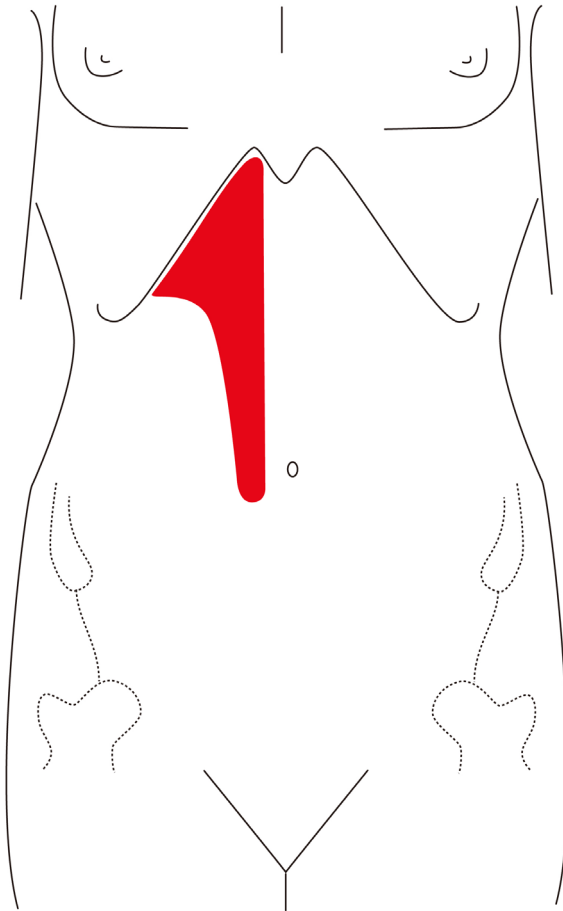
Right lower abdomen,
reaction in area around
McBurney point

Foot Jue Ying Mai



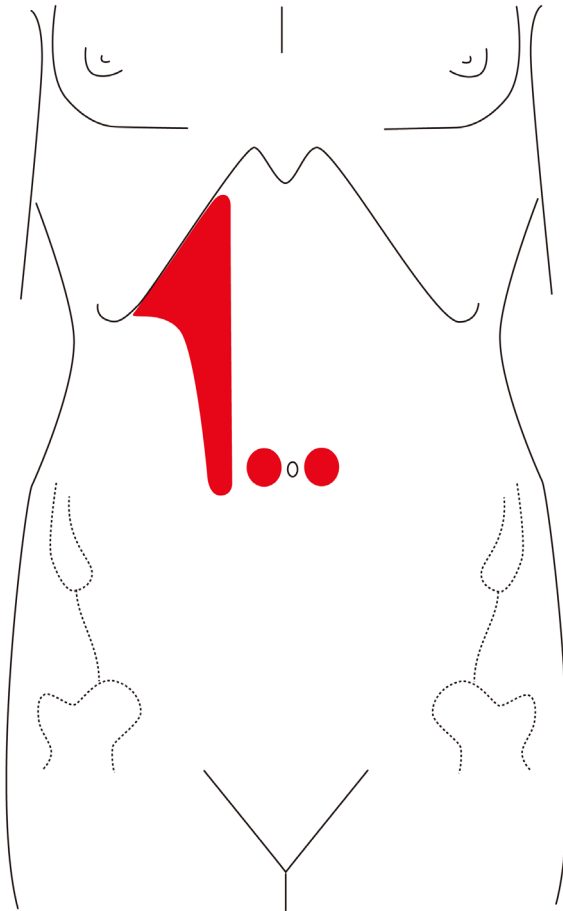
Area drawn from the left
intercostal rib running
into left ST25

Hand Shao Yin Mai



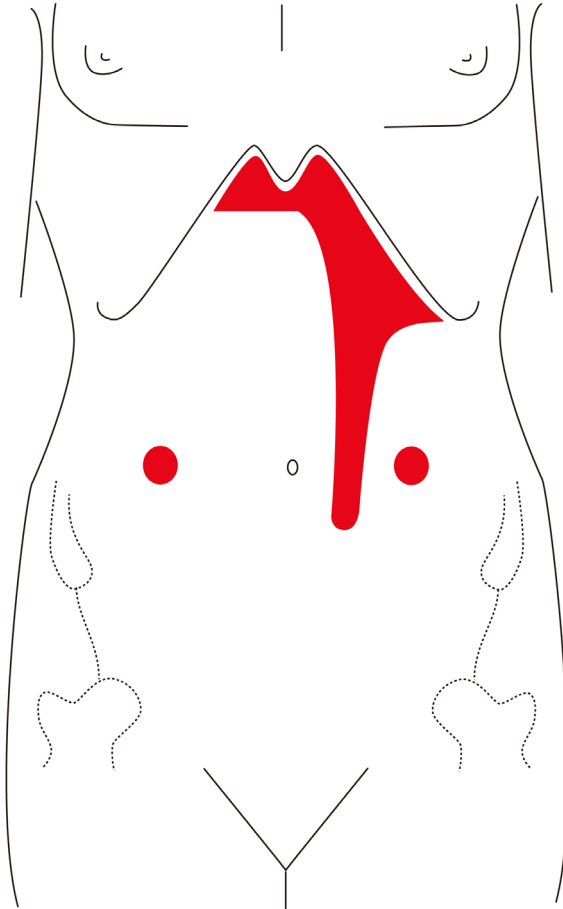
Area drawn from the
right intercostal rib, right
ST19, R ST20, R SP16 to R
ST25

HT5 – SP4



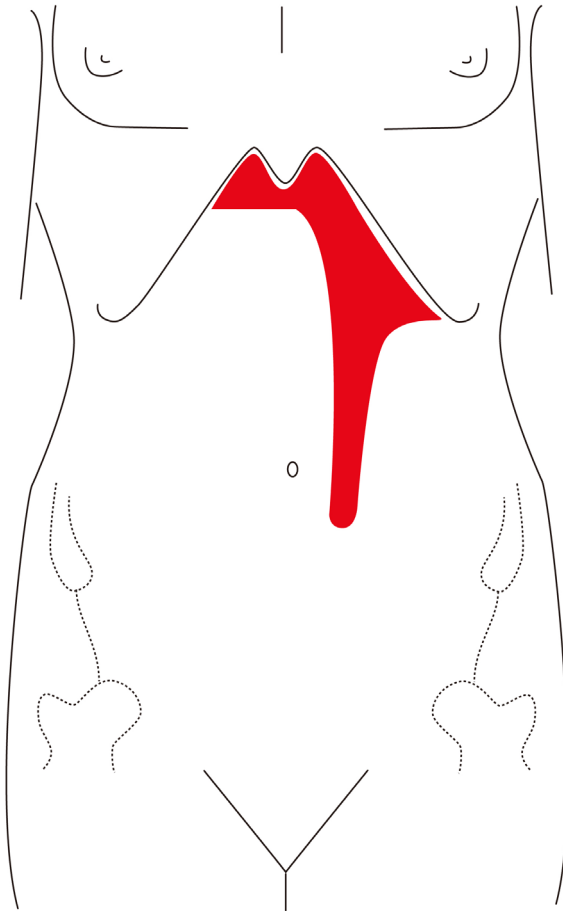
Hand Shao Yin (HT5-LV3)
reaction + pressure px
at .5 cun from the
umbilicus

PC6 – LV3



Reaction appears in area
from xiphoid running into
left ST25 and on SP15
(both sides)

LV3 – PC6



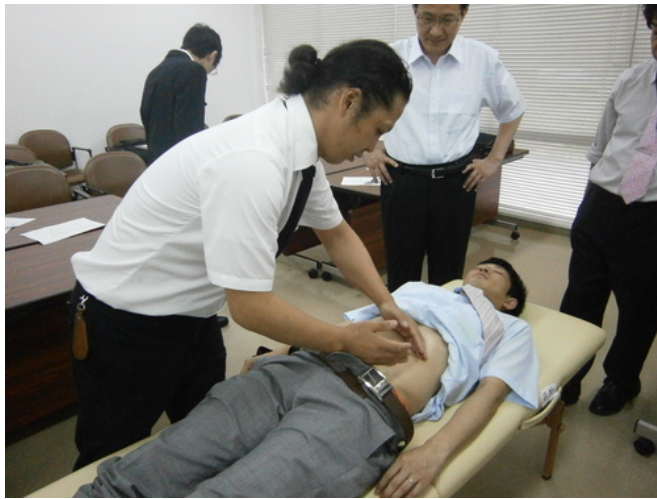Reaction appears in area from the xiphoid, left intercostals running into left ST25



STEP1

Intake

**Listening to the symptoms,
consider the general EV
pattern.**



STEP2

EV

Abdominal Diagnosis

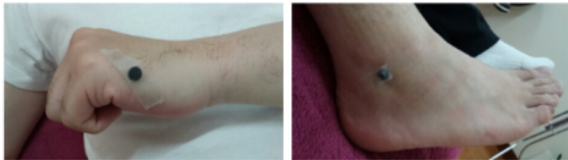Perform an EV abdominal examination and make an EV diagnosis.

STEP3

Place Testers

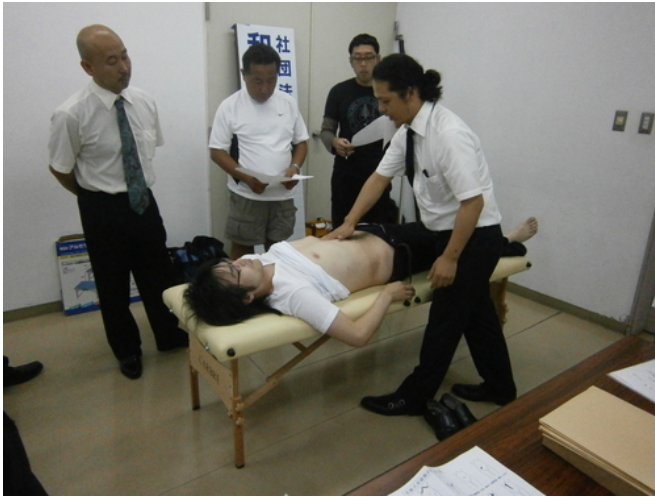

プラス(+)**の**テスター マイナス(-)**の**テスター



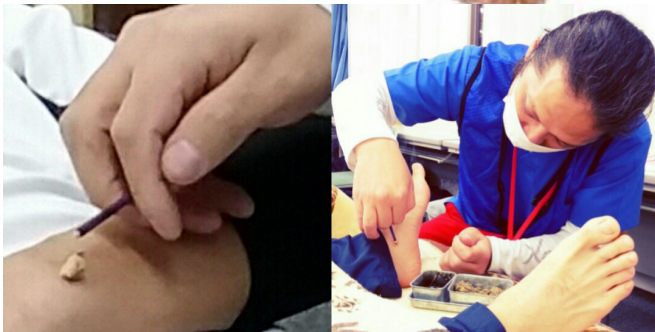
左後谿に+テスター 右申脈に-テスター

Once the pattern has been determined by EV abdominal examination, place EV testers on the points of the limbs to examine the changes.



STEP4 Check

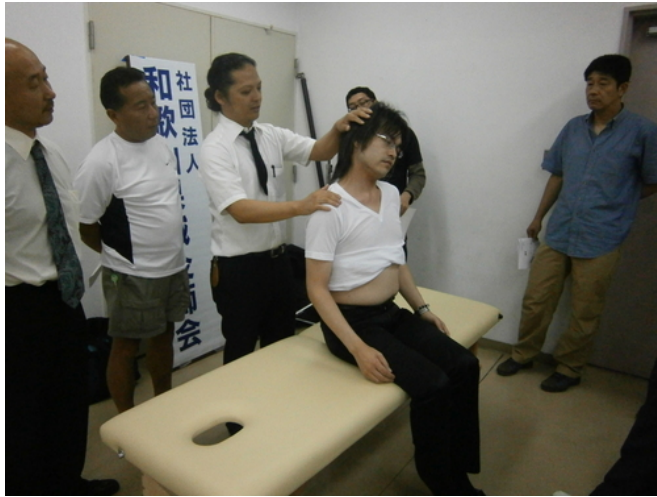Check for changes in the abdomen and symptoms.



STEP5

Treatment

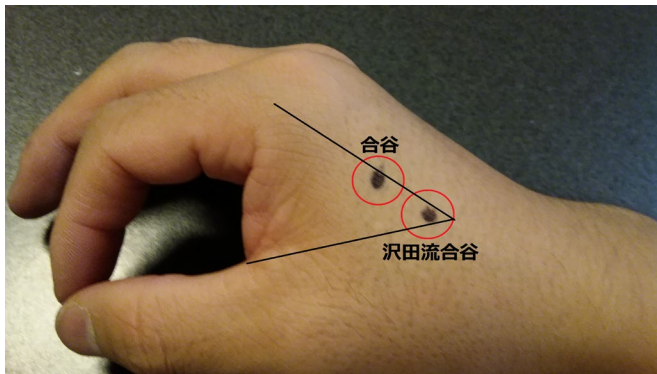
1. **Moxa: master point- 5 okyu, couple point- 3 okyu**
2. **Gold/Silver pressball: master point- gold, couple point- silver**



STEP6

Judge Efficacy

Lastly, check the symptoms.



STEP7

Home

Instruction

By giving a mark, the patient can do self care at home.